

OPIS PRZYPADKU/CASE REPORT

Otrzymano/Submitted: 27.04.2017 • Zaakceptowano/Accepted: 07.08.2017

© Akademia Medycyny

Role of nursing care of patient with Gaucher disease, with implanted venous access port – a case study**Paweł Więch¹, Karolina Suchy², Dariusz Bazaliński¹,
Monika Binkowska-Bury¹**¹ Institute of Nursing and Health Sciences. Faculty of Medicine, University of Rzeszow, Poland² Surgical Ward, Specialist Hospital MSWiA, Rzeszów, Poland**Abstract**

Background. Gaucher disease is a genetic metabolic disorder, associated with significant decrease in beta-glucocerebrosidase activity. Because of the large number of procedures related to venous access, nursing staff must have comprehensive expertise and practical training in this area. The rarity of Type 1 Gaucher disease as well as medical personnel's insufficient knowledge of the above problems inspired the authors of this article to describe a patient with this condition. **Case study.** We present a case report of a 24-year old female patient with extremely rare genetic metabolic disorder (Type 1 Gaucher disease), with a focus to the role of nursing staff in handling the implanted venous access port. In January 2015 the patient was subjected to a procedure which involved implantation of access device to the right internal jugular vein to enable regular administration of Cerezyme 1200 U (2 vials 400 units each, in 500 ml 0.9% NaCl via intravenous drip infusion). The applied device was a port with titanium chamber and 6.5F silicon catheter. The first puncture of the port was performed by the nurse on 26 Feb. 2015. Up until today, the procedure involving preparation and administration of the drug is performed every two weeks by the nursing personnel. *Anestezjologia i Ratownictwo 2017; 11: 291-295.*

Słowa kluczowe: Gaucher disease, venous access port, nurse

Background

Gaucher disease is a genetic metabolic disorder, associated with significant decrease in beta-glucocerebrosidase activity. Type 1, which is most frequently diagnosed, is characterized with liver and spleen enlargement, erythrocytopenia, thrombocytopenia as well as bone pain and deformities. Patients may experience chronic fatigue leading to decreased quality of life [1-3]. The disorder is linked with a higher risk of developing Parkinson's disease and gallbladder calculus in the future [3-4]. The main purpose of treatment is to minimize accumulation of toxic substrates of beta-glucocerebrosidase by applying Enzyme Replacement Therapy (ERT), which involves biweekly administra-

tion of imiglucerase [5-7].

Globally, prevalence of the disease is approximately 1/50,000 people, except for populations of Ashkenazi Jewish descent (1:850) [8]. In Poland (where this case study was elaborated) approximately 60 cases of the disease have been reported [7].

In the case of patients with Gaucher disease it is possible to implant a port enabling easy and comfortable intravenous access, yet in such situations nursing personnel is required to perform adequate preventive and diagnostic operations as well as treatments related to potential complications resulting from the use of the device. During hospitalization such risk of access-port related complications may be significantly reduced by nurses following the principles of asepsis, and having

expert knowledge of infusion, blood drawing, drug administration and parenteral nutrition. They are also responsible for the optimal choice of equipment – Huber needle with spoon-shaped tip cut and clamp, min. 10 ml syringe, sterile drape with gauze pads and an antiseptic, as well as sterile gloves, and occlusive dressing, when needed. In home environments, nurses are also responsible for instructing the patients and their families [9-10].

Because of the large number of procedures related to venous access, nursing staff must have comprehensive expertise and practical training in this area. The rarity of Type 1 Gaucher disease as well as medical personnel's insufficient knowledge of the above problems inspired the authors of this article to describe a patient with this condition. Indeed, the uniqueness of this case is magnified by the fact that the patient has an implanted venous access port. The study was designed to describe the role of a nurse in the care of a patient with Gaucher disease and implanted venous access port and to improve the knowledge of this aspect among medical personnel, including nursing staff.

Case Study

The study focuses on a 24-year-old female patient with an implanted venous access port, receiving treatment due to genetically conditioned Type 1 Gaucher disease. Out of four siblings, only her younger brother also suffers from the same condition. Since childhood the patient has been receiving hematologic treatment due to anaemia. In 2012 bone-marrow punch biopsy was performed and the disease was confirmed by genetic tests; subsequently an application was sent to Coordination Team for Ultra-Rare Diseases at *Centrum Zdrowia Dziecka* Hospital in Warsaw, in order to enrol the patient for Gaucher Disease Treatment Programme, involving use of enzyme replacement therapy based on β -glucocerebrosidase (imiglucerase). During qualification process she was subjected to a number of examinations: magnetic resonance imaging (MRI) of the head, electrocardiography (ECG), abdominal and retroperitoneal ultrasound examination (USG), X-ray of the chest, shoulder, arm, and pelvis, as well as echocardiography. Additionally, psychological tests, as well as neurological and ophthalmological examinations were conducted. After she was finally approved for the programme, in October 2013 the patient received the first dose of imiglucerase, in the form of Cerezyme

- 2 vials 400 units each in 500 ml 0.9% NaCl via intravenous drip infusion. The applied treatment was well-tolerated; further recommendations included self-observation, well-balanced lifestyle, and biweekly visits to the hospital to receive subsequent doses of the drug. In accordance with the applied therapy, for a period of approximately 1.5 years the drug was administered by drip infusion to peripheral veins. After this period the patient was approved for a procedure of venous access port implantation, with recommended causal treatment (imiglucerase infusion) due to limited access to peripheral veins and the necessity to frequently apply intravenous infusion.

The patient had history of hospitalization due to vesicoureteric reflux (ureteral reposition at the age of 8) and strabismus correction (at the age of 5, 14 and 16 yrs). In childhood she was diagnosed with bronchial asthma, allergy to dust, animal hair and grass. In addition, the patient had a 3.5 mm pineal cyst.

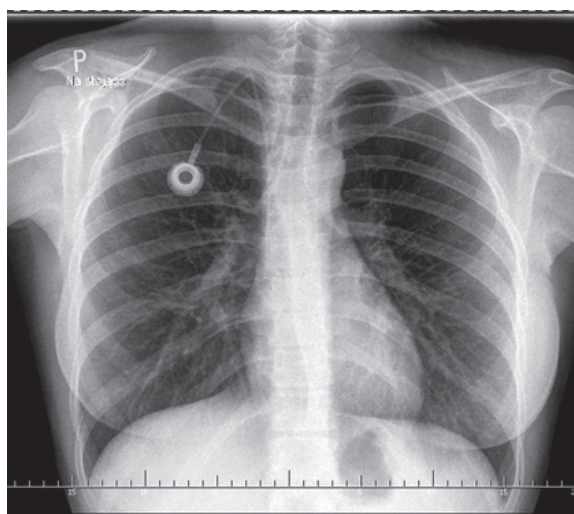


Figure 1. Location of venous access port in X-ray image (source: the patient's records)

In January 2015 the patient was subjected to the procedure which involved implantation of access device to the right internal jugular vein. The applied device was a port with titanium chamber and 6.5F silicon catheter. The procedure was performed under local anaesthesia. Radiological examination showed the end of the catheter, running from the portal, at the entry to the right atrium of the heart (figure 1). No complications occurred during the post-operative period. The access was filled with 500 U/ml heparin solution and

the dressing was changed. The patient was discharged home in good condition with a recommendation to follow up after 10 days to remove stitches.

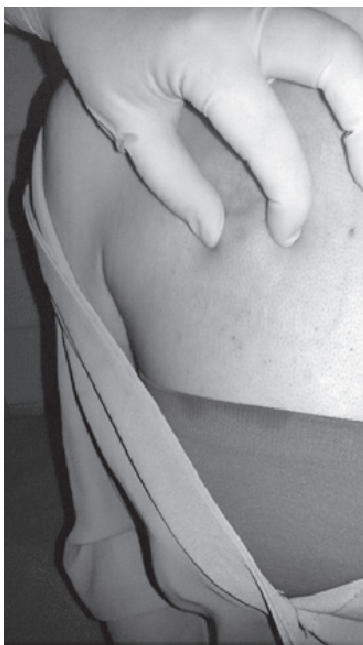

Figure 2. Venous access port palpation (photo taken by the authors)

On 26 Feb. 2015 a nurse performed the first puncture of the port to administer the drug. At present (mid-2016) there are no complications due to the implanted port, yet the woman has reported pain in her wrists and shin bones, which suggests aggravation of the disease. The patient feels pain when the needle is being inserted; because of this Emla cream for topical anaesthesia is applied before the administration of the drug by drip infusion is started. The patient receives 1200 U of Cerezyme, dissolved in 500 ml of saline solution, via drip infusion into the access port. During the observations, the patient's venous blood was drawn via the port for a number of tests (chitotriosidase level, complete morphology, coagulation system, liver function) necessary for the patient's subsequent qualification for the treatment program (performed every six months). Other conducted examinations included abdominal ultrasound, ECG and neurological consultation. The patient reports frequent fatigue as well as bone and joints pain – in the write wrist, left hip, spine and bilateral pain in lower legs; she was referred for MRI examination of the wrist, and received recommenda-

tions for reducing physical activity.

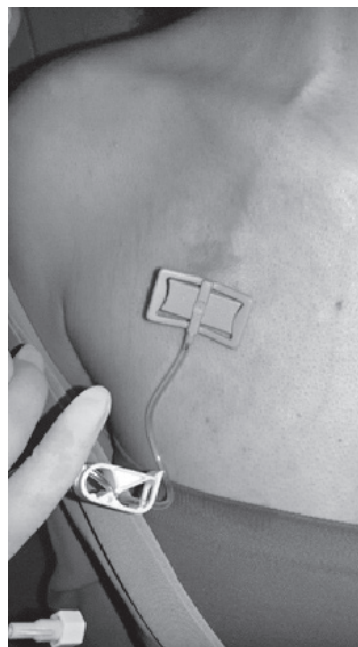


Figure 3. Huber needle in the port chamber (photo taken by the authors)

At present the patient reports for the biweekly administration of the drug via the venous access port. The procedure of preparing and administering the solution is carried out by nursing personnel (figures: 2 and 3). The main current health problems in the patient include: pain caused by skin puncture over the port with Huber needle, patient's anxiety of possible complications, insufficient knowledge of the care of the port and all possible complications related to the use of the port.

Discussion

The case study concerned the patient with Gaucher disease with implanted venous access port due to frequent need for infusion and limited peripheral vein access. During nursing care, problems were reported by the patient related to the implanted venous access port. The first one involved pain during port puncturing with Huber needle. The pain relief guidelines require anesthesia of the skin over the port chamber by applying Emla cream about 2 hours before puncturing and protection with occlusive dressing [11]. In addition, the reduction of pain can be achieved by performing

the procedure in accordance with the requirements of the venous access port manufacturer and the current standards of care in this field. The recommendations point to the use of Huber needle that has a specific shape which does not cut the silicone diaphragm but delaminates it. The needle wings should adhere to the skin of the patient. Good placement of the needle in the port also includes its attachment with sterile, preferably transparent dressing [12].

Another problem reported by the patient was the concern about possible complications and their consequence related to the use of the port. Adhering to the rules of asepsis and antiseptics is crucial while performing this type of procedure. Washing and disinfection of the hands by a nurse managing the port is mandatory to minimize the risk of infection [10,13]. Cieśla and Czerniak emphasize that preparation of a set of necessary tools and drugs should be performed in sterile conditions. It is important to use the right disinfectant, especially at the site of injection and in hand disinfection. According to the authors, the procedure of hand washing and hygiene behavior, although well-known and widespread, is often neglected by medical personnel [14]. An important issue in preventing the onset of catheter infection is to disinfect the puncture site three times, as shown in Krężelewska's paper. Disinfection should be done using the agent used in the ward and using a protective liner with the opening in which the port compartment should be located [15]. According to Nicpoń et al., 2% chlorhexidine solution should be used for skin cleansing. It should be noted that early diagnosis of venous access port infection allows for the implementation of appropriate antibiotic therapy and provides the opportunity to preserve the port [13]. In the described case of the patient with Gaucher disease, the skin was disinfected three times in course of cyclic port puncturing using Kodan agent (active ingredients: 2-propanol, 1-propanol, 2-diphenyl) available in the ward. Care should be taken with the application of greasy and nourishing creams. Also skin tension over the port chamber should be avoided [13,15-16].

Patient's anxiety related to the occurrence of

complications was associated with lack of knowledge about the complications and proper care of the port. The solution of these problems should be the educational role of a nurse. All patients should be informed of complications related to the presence of the port. These include mainly infectious and thrombotic complications, as well as catheter migration or membrane damage [13,17].

In the process of providing medical care to the patient with Gaucher disease, with an implanted venous access port, nurses are responsible for handling and maintenance of the access device. They watch the port for signs of infection or thrombosis, and by following the principles of asepsis and antisepsis they minimize the risk of complications. Each time at the end of the infusion the nurse applies heparin lock, and then removes the needle under positive pressure, preventing blood return into the catheter. The patient with implanted port is informed by the nurse about any procedures performed, and about the care of the access device and the skin in its area, in order to decrease anxiety and reduce the gap in knowledge related to the patient's venous access port [9-10].

Funding

The study was performed within the project 'Centre for Innovative Research in Medical and Natural Sciences' realized by University of Rzeszów, co-financed within Regional Operational Programme for the Podkarpackie Province for the years 2007-2013, contract number UDA-RPPK.01.03.00-18-004/12-00.

Conflict of interest

None

Correspondence address:

✉ Paweł Więch

Institute of Nursing and Health Sciences
Faculty of Medicine, University of Rzeszów
2 W. Kopisto; 35-310, Rzeszów, Poland

☎ (+48 17) 872 11 53

✉ p.k.wiech@gmail.com

References

1. Dandana A, Khelifa SB, Chahed H, et al. Gaucher Disease: Clinical, Biological and Therapeutic Aspects. *Pathobiology*. 2016;83:13-23.
2. Essabar L, Meskini T, Lamalmi N, et al. Gaucher's disease: report of 11 cases with review of literature. *Pan Afr Med J*. 2015;20:18.
3. Chen Zion Y, Pappadopulos E, Wajnrajch M, Rosenbaum H. Rethinking fatigue in Gaucher disease. *Orphanet J Rare Dis*. 2016;11:53.
4. Bennett LL, Turcotte K. Eliglustat tartrate for the treatment of adults with type 1 Gaucher disease. *Drug Des Devel Ther*. 2015;9:4639-47.
5. Nagral A. Gaucher Disease. *J Clin Exp Hepatol*. 2014;4:37-50.
6. Rizk TM, Ariganjoye RO, Alsaeed GL. Gaucher disease. Unusual presentation and mini-review. *Neurosciences*. 2015;20(3):271-6.
7. Jędrzejek M, Wiślińska K, Swider G. Choroba Gauchera - problem diagnozy oraz ocena skuteczności leczenia enzymatycznego. Prezentacja 4 przypadków [Gaucher disease – diagnostic difficulties and assessment of enzyme treatment effectiveness. Presentation of four cases]. *CPM*. 2012;27:105-12.
8. Hagit N, Baris MD, Cohen IJ, et al. Gaucher Disease: The Metabolic Defect, Pathophysiology, Phenotypes And Natural History. *Pediatr Endocrinol Rev*. 2014;12(01):72-81.
9. Paleczny J, Banyś-Jafernik B, Gazurek K, et al. Long-term totally implantable venous access port systems - one center experience. *Anaesthesiol Intensive Ther*. 2013;45(4):215-22.
10. Biedna E. Pielęgnacja dostępów naczyniowych u pacjentów onkologicznych [Care of venous access devices in oncological patients]. *Opieka onkologiczna* 2015;3(6):8-12.
11. Młynarski R. Zastosowanie portów dożylnych w opiece paliatywnej [Use of intravenous ports in palliative care]. *Nowa Med*. 2004;2.
12. Góraj EJ, Misiak M. Zastosowanie wszczepialnych portów naczyniowych – wskazania, obsługa, pielęgnacja i powikłania [Use of implantable vascular ports - indications, handling, care and complications]. *Med Paliat*. 2013;5(3):93-105.
13. Nicpoń J, Kaczmarek-Borowska B, Pelc M, Freygant K. Żyłne cewniki centralne a powikłania [Complications of venous central catheters]. *Prz Med Uniw Rzesz Inst Leków*. 2014;1:97-106.
14. Cieśla D, Czerniak J. Możliwości zapobiegania zakażeniom odcewnikowym [Prevention of catheter infections]. *Pielęg Chir Angiol*. 2008;3:110-2.
15. Krężelewska H. Profesjonalna opieka pielęgniarska nad pacjentem z chorobą nowotworową z wszczepionym portem naczyniowym. W: *Opieka onkologiczna [Professional nursing care for a cancer patient with an implanted vascular port in: Oncological Care]*. 2015;4(7):24-30.
16. Goździk J. Porty naczyniowe – zastosowanie kliniczne [Vascular ports - clinical use]. *Przew Lek*. 2007;1:98-103.
17. Barwińska-Pobłocka K, Wydra D, Abacjew-Chmyłko A, Szkop-Dominiak A. Zastosowanie portów naczyniowych u chorych onkologicznych [Use of vascular ports in oncological patients]. *Ginek Pol*. 2013;84:339-43.