

## ARTYKUŁ ORYGINALNY/ORIGINAL PAPER

Wpłynęło/Submitted: 02.11.2011 • Poprawiono/Corrected: 16.11.2011 • Zaakceptowano/Accepted: 18.11.2011

© Akademia Medycyny

**Six places to avoid with your epidural catheters in obstetric practice; the radiological evidence****Clive B. Collier**

Prince of Wales Private Hospital, Sydney, Australia

**Abstract**

Even the most experienced anaesthetists will occasionally insert epidural blocks that fail or are complicated by a life-threatening event, particularly in the field of obstetric anaesthesia. Our use of post-partum contrast injection and fluoroscopy to investigate such cases has enabled us to determine six sites where an epidural catheter may be displaced; these being the intravascular, subarachnoid, subdural and intradural spaces, as well as escape through an intervertebral foramen, or displacement by a septum. Accurate diagnoses will not be made if these cases are not investigated radiologically. *Anestezjologia i Ratownictwo 2011; 5: 419-424.*

*Keywords: epidural anaesthesia, complications, epidural catheter, intradural space, subdural space*

**Introduction**

In 1990, the subdural space was described as the third place for an epidural block to go astray, in addition to the subarachnoid space and intravascular injection, all with potentially life-threatening results. Our radiographic and anatomical studies have recently led us to describe a fourth place of interest, the 'intradural space', where epidural needles or catheters may be introduced within the substance of the dura. In addition, there are two other sites into which an epidural catheter may be inserted which will result in failed or inadequate blocks (Table 1).

Table 1. The 6 places to avoid

- |   |
|---|
| <ol style="list-style-type: none"> <li>1. Intravascular</li> <li>2. Subarachnoid</li> <li>3. Subdural</li> <li>4. Intradural</li> <li>5. Catheter escape</li> <li>6. Obstruction by a septum</li> </ol> |
|---|

One site is within the epidural space, with a septum preventing the normal spread of local anaesthetic solutions, and the other is outside the epidural space, following the 'escape' of an epidural catheter through an intervertebral foramen.

**Methods**

We have undertaken epidurogram studies on obstetric and gynaecological patients over the past 30 years, following an ethics committee's approval, and have currently accumulated a mass of imaging data on 190 cases [1]. Following informed consent, we investigated cases of failed, inadequate, complicated and atypical blocks within 24 hours of their epidurals, by injecting 10-13 mL of contrast (currently, Isovue 300, Bracco Diagnostics Inc.) through the epidural catheter, under fluoroscopic screening in the Radiology Department.

**Results****The normal epidurogram**

In the anteroposterior (AP) view, injection of 10-13 mL of contrast is seen to produce the classical

'Christmas-tree appearance' (Figure 1), with the 'tree-trunk' spread over approximately eight or nine vertebral levels, typically six or seven vertebral segments cephalad to the catheter tip, and one or two caudal to it.

The characteristic appearance of the 'tree-trunk' is that of a body of contrast usually much denser in its lateral aspects than in the midline. The 'branches' are composed of contrast spreading around the spinal nerves, and then emerging through the intervertebral foramina and running laterally for a variable distance.

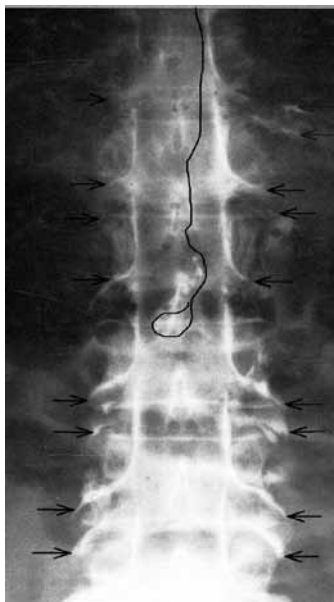


Figure 1. Typical AP (anteroposterior) epidurogram with 'Christmas tree appearance' from T4 to L5. The transforaminal escape of contrast at several vertebral levels is arrowed

#### ▪ Intravascular injection

All anaesthetists should be aware of the effect of injection of local anaesthetic into an epidural vein. The expected features are a metallic taste in the mouth and numbness of the tongue, followed by restlessness and other signs of CNS (central nervous system) stimulation, such as muscle twitching prior to the onset of convulsions. CNS depression may follow with unconsciousness, and cardiovascular depression. However, with the widespread introduction of low-dose continuous infusions of local anaesthetics (LA) in labour, it has recently become apparent that small volumes of diluted local anaesthetic may be leaking

into epidural veins, over several hours, with the patient showing remarkably few symptoms or signs apart from a little light-headedness. The true situation has been revealed, on two occasions, where top-up doses of lidocaine 2%, for emergency caesarean section, have resulted in the immediate onset of convulsive activity. Attempts to aspirate blood prior to LA injection were unsuccessful in both cases. One case involved the use of a catheter with 3 lateral eyes, and the other a terminal hole catheter.

Demonstration of intravascular placement of an epidural catheter may be difficult radiologically, as usually only a faint, short-lived 'plume' of intravenous contrast is detected by fluoroscopy.

#### ▪ Subarachnoid injection

The classical picture of an accidental total spinal (subarachnoid) block, with early and dramatic collapse of the patient accompanied by apnoea and unconsciousness, is usually impossible to mistake for any other situation, especially if cerebrospinal fluid (CSF) can be aspirated through the catheter. However, the current use in labouring women of dilute solutions of local anaesthetics, (often combined with an opioid), may produce a different and slower sequence of events when injected into the subarachnoid space, with only a high thoracic-level block developing, and possibly dense motor block in the legs. Diagnosis may be difficult, especially if CSF cannot be aspirated, as frequently happens, at least initially. In these situations, or cases of suspected multi-compartment block [1,2] or associated intradural block (see below), there is a diagnostic role for epidurography, even when CSF can be freely aspirated. Without investigation, unusual outcomes that may advance our knowledge of the relevant anatomy will be missed. One such case, for example, involved contrast spreading from the intradural space to the subarachnoid space in a patient who had presented with a late-onset total spinal block following a top-up dose, 80 minutes after the original satisfactory epidural block [1]. Investigation may not benefit the individual patient, as a significant anatomical abnormality is unlikely to be present, but it may offer a clue as to why the subarachnoid space was inadvertently entered, of whether the epidural catheter was correctly sited but then migrated.

On radiographic screening, subarachnoid injection has a very distinctive appearance (Figure 2), with a moderately dense, extensive column of contrast

that fills most of the subarachnoid space, but is fairly featureless apart from some parallel 'linear streaking' representing the emerging nerve-roots. The absence of foraminal spill is obvious. The characteristic horizontal upper level of contrast may be seen in some cases, and this level may move with changes in patient position.

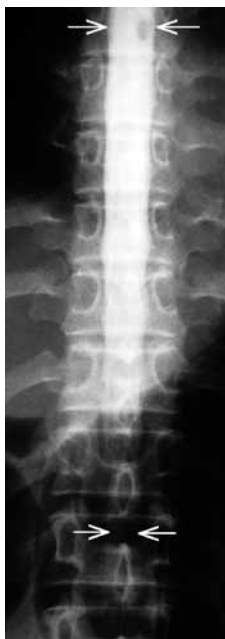

Figure 2. AP radiograph following 6 mL injection, with a mass of subarachnoid contrast extending from T7 to L2 (arrowed)

#### ▪ Subdural injection

It is time that the subdural space no longer be described as a 'potential space'. Through the work of Reina and others [3], it has been demonstrated that a subdural space is created by trauma from an epidural needle or catheter inserted too deeply – the subdural (extra-arachnoid) compartment is entered and prised open. The resulting space may spread upwards over a short vertical distance, or in extreme cases intracranially and as high as the floor of the third ventricle, covering a remarkable distance of 30-40 cm. Such extreme cases are rare but well-documented [1], occurring in approximately 1 in 3,000 obstetric cases featuring the slow onset of high neuraxial block, over 20-40 minutes, with apnoea and unconsciousness but only minimal hypotension. Less extensive subdural spread almost certainly occurs more commonly, but as it may only produce dense lower limb motor block,

and is rarely investigated, an accurate diagnosis is not made.

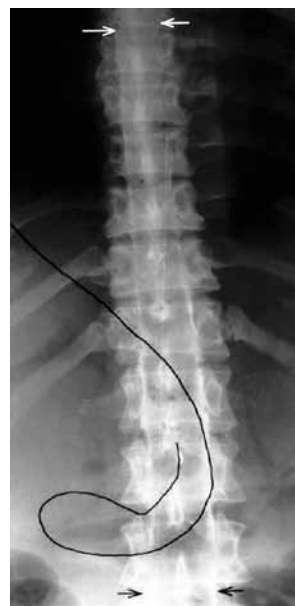

Figure 3. AP epidurogram, following a high block, with bilateral subdural columns of contrast from T4 to L4 (arrowed)

The x-ray appearance of subdural contrast is occasionally unilateral, but more commonly bilateral (Figure 3). In the latter situation, two thin, wispy columns of contrast form the characteristic 'rail-road tracks'. This pattern of contrast distribution appears to result from the subdural space tending to spread laterally as it opens up, and accounts for the preferential accumulation of contrast adjacent to the spinal nerve-roots. Here, there is a sharp cut-off to the flow of contrast, which does not extend beyond the vertebral bodies, and there is no foraminal spill. Although the vertical spread of contrast – and presumably local anaesthetic – is fairly rapid, the onset of subdural block is delayed by over 20 minutes following injection, reflecting the time taken for the local anaesthetic to traverse the arachnoid.

#### ▪ Intradural injection

Whereas accidental injection of local anaesthetic into the subdural space usually produces an extensive block that may be life-threatening, local anaesthetic injected into the substance of the dura, to create an intradural space, appears to form a localised and

swelling collection within the layers of the dura. This may cause transient pain and at least initially produces only a restricted neuraxial block. Repeated doses of local anaesthetic may escape retrogradely from the intradural space to the epidural space around the outside of the epidural catheter, eventually producing a clinically acceptable block. However, there is a slight risk of an extensive block developing some time later, following rupture of the remaining layers of dura and sometimes the arachnoid as well, leading to diversion of the intradural solution into the subdural or subarachnoid spaces [1]. Careful patient monitoring and repeated aspiration of the catheter for CSF are advised whenever several doses of local anaesthetic are required to correct an inadequate block.

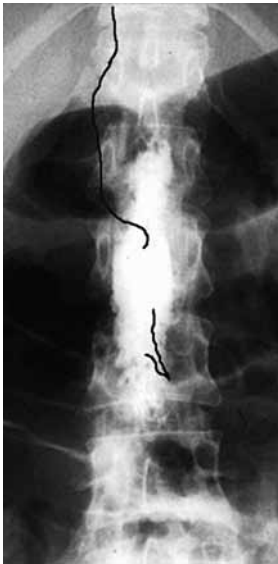

Figure 4. AP epidurogram of thoracolumbar spine showing dense 'sausage-shaped' mass of intradural contrast

The radiographic findings (Figure 4) are of a dense localised collection of contrast forming a sausage-like mass, extending over 1-3 vertebral segments. Injection of contrast, or local anaesthetic, is often associated with back pain, presumably due to compression of the underlying cauda equina by the swelling mass. Some practitioners are reluctant to accept that the dura mater, which has a thickness of up to 0.5 mm (500  $\mu\text{m}$ ), can accommodate within its thickness an epidural catheter of almost twice its diameter. However, the nature of the composition of the dura, with its concentric laminae

containing collagen fibres, allows for the suggestion that it is dural laminar detachment, or 'delamination', that is the major factor in the formation of intradural spaces [4] (Figure 5).

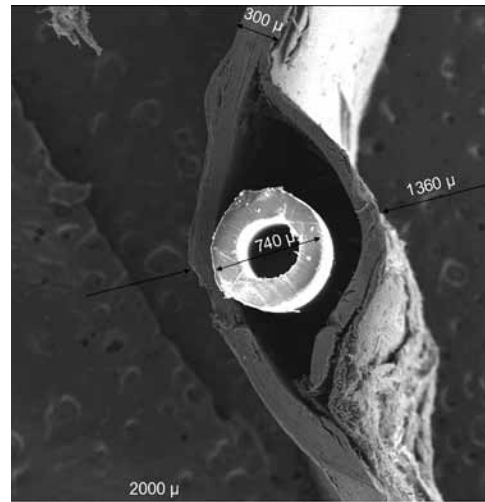

Figure 5. Scanning Electron Microscope Image of an epidural catheter within the dura (intradural) (x25) showing a dural thickness of 300 $\mu\text{m}$  and a combined width of dura and catheter of 1360 $\mu\text{m}$

#### ▪ Catheter escape

Transforaminal catheter 'escape' may be complete or partial (Figure 6). With a complete escape, the catheter-tip exits the epidural space and comes to rest on the paravertebral muscles, with any resulting nerve block arising from LA spread to the adjacent lumbar plexus. On radiological examination, escaping contrast usually highlights the psoas muscle. With partial escape, where one or more of the catheter eyes (or openings) remain inside the epidural space, restricted and patchy unilateral blocks occur, and clinical diagnosis may be difficult. Catheter escape represents the commonest form of epidural block failure, being found in about 13% of our unsatisfactory blocks [1]. Escape is seen more often with the use of more rigid types of catheter, as these are more easily diverted from the midline following their insertion than softer catheters, which tend to form a coil around the midline [5]. The insertion of excessive lengths of catheter, i.e. more than 7 cm into the epidural space, also seems to predispose to escape, as does the presence of even minor degrees of scoliosis, of which the patient is often unaware [1].

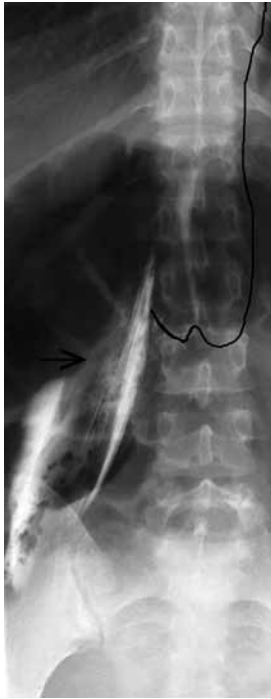

Figure 6. AP epidurogram following catheter escape through the right L2-3 intervertebral foramen, with contrast outlining the right psoas muscle (arrowed)

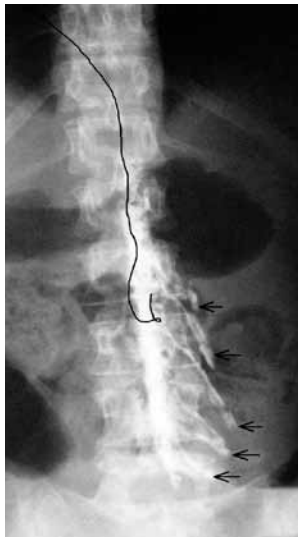

Figure 7. AP epidurogram with almost totally left-sided spread of contrast from L1 to L5 and profuse left foraminal spill (arrowed). Appearance suggestive of a midline septum

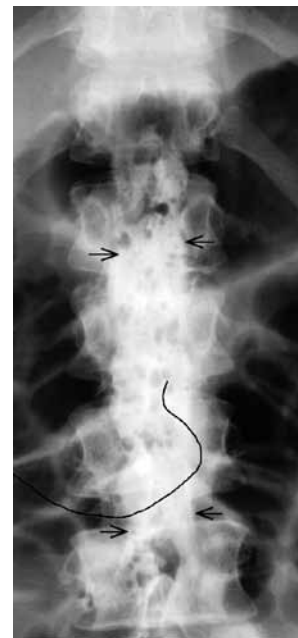

Figure 8. AP epidurogram showing a dense collection of contrast from L1 to L4 (arrowed), with characteristic scalloped edges and minimal foraminal spill, suggestive of a transverse septum

Where catheter escape is suspected, withdrawal of the catheter by 1-2 cm and injection of further LA will lead to a satisfactory block in about 50% of cases. In the remainder, the block is not improved, as the LA dose appears to follow the original path of the catheter out of the epidural space, as demonstrated by contrast injection and fluoroscopy.

#### ▪ Obstruction by a septum

A significant (dorsal) midline septum (Figure 7) appears to exist in 2-3% of our patients [1], and is a fairly frequent cause of predominantly unilateral blocks, whereas a transverse (or 'lateral') septum (Figure 8), which is usually but not always associated with a midline septum, tends to impede the vertical spread of epidural solutions, so blocks may be insufficiently high, or alternatively fail to block sacral roots. An unsatisfactory block due to a septum may often be at least partially corrected by increasing the dose of LA, although the possibility of an extensive, usually unilateral block, should be anticipated with a midline septum. Withdrawal of the epidural catheter by 1-2 cm prior to LA administration may also improve the block in some instances.

## Conclusion

The investigation of unusual epidural blocks is only undertaken by a handful of practitioners, and it would be of enormous value if more anaesthetists did study their own complications or failures. An epidurogram carries minimal risk to the patient (as long as contrast-sensitive individuals are excluded) or the breast-fed neonate, and can be undertaken in any radiology department and takes less than 10 minutes. The most benefit arises if the anaesthetist involved injects the contrast themselves and watches the spread on fluoroscopy – it can be most enlightening! MRI and CT scans are fairly unhelpful from the anaesthetist's point of view, as it is observation of the flow of contrast that is

most revealing. Only by further investigation will our knowledge of the complexities of epidural anaesthesia, and the six places to avoid, be significantly advanced.  
Correspondence address:

Clive B. Collier  
Prince of Wales Private Hospital  
Barker Street, Randwick, NSW 2031  
Sydney, Australia

☎ 02 9650 4000  
✉ nfil@pacific.net.au

**Konflikt interesów / Conflict of interest**  
Brak/None

## References

1. Collier CB. Epidural Anaesthesia: Images, Problems, Solutions. London: Hodder Arnold; 2011.
2. Beck H, Brassow F, Doehn M, Bause H, Dziadzka A, Schulte Am Esch J. Epidural catheters of the multi-orifice type. Dangers and complications. *Acta Anaesthesiol Scand* 1986;30:549-55.
3. Reina MA, de Leon-Casasola O, López A, de Andrés JA, Mora M, Fernández A. The origin of the spinal subdural space: Ultrastructure findings. *Anesth Analg* 2002;94:991-5.
4. Collier CB, Reina MA, Prats-Galino A, Maches F. An anatomical study of the intradural space. *Anaesth Intensive Care* 2011;39:1038-42.
5. Spiegel JE, Vasudevan A, Li Y, Hess PE. A randomised prospective study comparing two flexible epidural catheters for labour analgesia. *Br J Anaesth* 2009;103:400-5.