

OPIS PRZYPADKU / CASE STUDY

Otrzymano/Submitted: 30.04.2024 • Zaakceptowano/Accepted: 15.05.2024

© Akademia Medycyny

Extracorporeal Cardiopulmonary Resuscitation (ECPR) for in-hospital cardiac arrest (IHCA) in pediatric patient with heart failure resulting from a previously unrecognized dilated cardiomyopathy**Aleksandra Kalicka¹ , Michał Buczyński³ , Maciej Kaszyński² , Izabela Pągowska-Klimek²**¹ Student Scientific Club „Ankona Pediatryczna” at the Department of Pediatric Anesthesiology and Intensive Care, Medical University of Warsaw² Department of Pediatric Anesthesiology and Intensive Care, Medical University of Warsaw³ Department of Heart, Thoracic and Transplant Surgery, Medical University of Warsaw**Abstract**

Introduction. Pediatric in-hospital cardiac arrest (IHCA) has a significant morbidity and fatality rate. Extracorporeal cardiopulmonary resuscitation (ECPR) is a salvage method in which extracorporeal membrane oxygenation (ECMO) is performed immediately on patients who have experienced cardiac arrest (CA) and have failed conventional cardiopulmonary resuscitation (CCPR). **Case reports.** The 7-month-old infant was admitted to the hospital due to heart failure resulting from a previously unrecognized dilated cardiomyopathy. IHCA occurred due to ventricular fibrillation. Despite five defibrillations, only brief returns to a hemodynamically competent heart rhythm were achieved. The child was transferred to the operating room for ECMO placement, successfully maintained for a week without complications. **Discussion.** ECPR is rather a last-resort therapeutic option for certain patients in settings when it is available. With the widespread use of ECPR, an increasing number of patients could survive cardiac arrest. **Summary.** ECPR is a viable treatment for cardiac arrest and should be considered in the early stages of CPR. *Anestezjologia i Ratownictwo 2024; 18: 90-94. doi:10.53139/AIR.20241810*

Keywords: cardiac arrest, cardiopulmonary resuscitation, extracorporeal cardiopulmonary resuscitation, extracorporeal membrane oxygenation, pediatrics

Introduction

Global data on the incidence, circumstances, and outcomes of cardiac arrest in children is currently lacking in accuracy [1]. It is crucial to acknowledge that the statistics regarding pediatric cardiac arrest can vary significantly based on regional differences, population demographics, and variations in reporting methodologies.

Pediatric in-hospital cardiac arrest (IHCA) is a rare event but associated with high mortality [2].

Extracorporeal Cardiopulmonary Resuscitation (ECPR) is a second line, salvage therapy for patients suffering cardiac arrest resistant to conventional resuscitation. ECPR aims to optimize cardiac output and organ perfusion to improve survivability and neurological outcomes following cardiac arrest [3]. This case report highlights the successful management of a pediatric patient who experienced a cardiac arrest due to previously unrecognized dilated cardiomyopathy with the use of venoarterial ECMO support.

Case reports

The 7-month-old infant was admitted to the hospital due to feeding aversion and increased respiratory rate. Chest X-ray revealed a significantly enlarged cardiac silhouette (CTR 0.75). Anemia was diagnosed, accompanied by elevated NT-proBNP (>70,000 pg/ml) and troponin levels (175 pg/ml; normal range <15.6 pg/ml).

The ambiguous medical history indicated gradual growth restriction observed by the mother since the child's second month of life. Birth weight was 4030 g; current weight was 7.5 kg with a height of 75 cm. Alarming symptoms included breast refusal, limited food intake, and interruptions during breastfeeding attempts. Symptoms exacerbated two days before admission, primarily manifesting as worsened respiratory distress and refusal of food. A month earlier an infant suffered from an upper respiratory tract infection with a fever of 37.5 °C and nasal congestion.

At admission milrinone infusion (0.7 micrograms/kg/min) and furosemide were prescribed. The following evening, the infant experienced a decline in oxygen saturation to a minimum 80% during deep sleep. High flow nasal therapy was initiated, but the infant did not tolerate it and kept removing the nasal cannula. It was replaced with an oxygen mask, effectively achieving saturation levels above 90%.

Next morning, the on-call doctor was summoned due to child's unresponsiveness with pale skin and undetectable pulse. Electrocardiogram revealed ventricular fibrillation. Resuscitation was started. Prompt intervention included intubation, mechanical ventilation, defibrillation and the suction of residual feeds. Repeated boluses of adrenaline and amiodarone were administered. Despite five defibrillations, only brief returns to a hemodynamically competent heart rhythm were achieved. Echocardiography showed no pericardial fluid, weak atrial contraction, minimal movement of basal heart segments, dilated, akinetic apex. The child was transferred to the operating room for venoarterial ECMO (VA-ECMO) placement (figure 1). Drainage cannula was placed in right atrium and the return cannula – in ascending aorta (figure 2).

Following the procedure, the patient was in an extremely critical condition, on full ECMO support with infusions of adrenaline, noradrenaline, dopamine

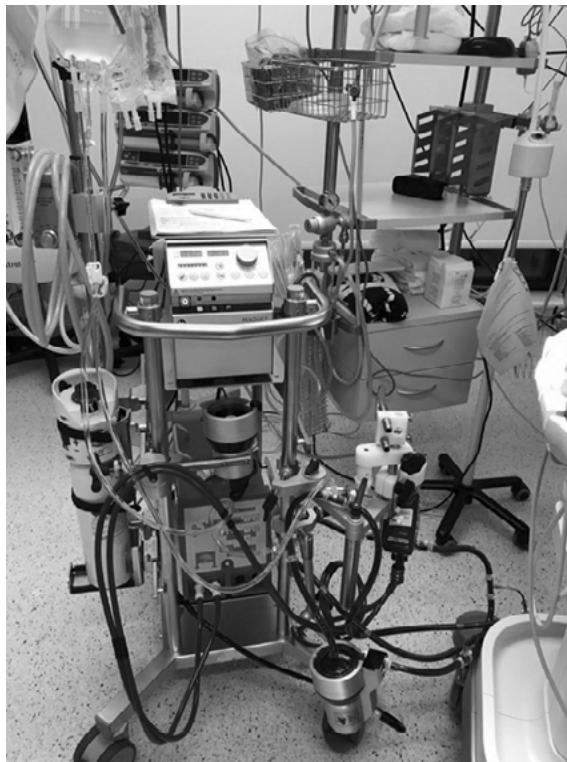

Figure 1. The extracorporeal membrane oxygenation machine

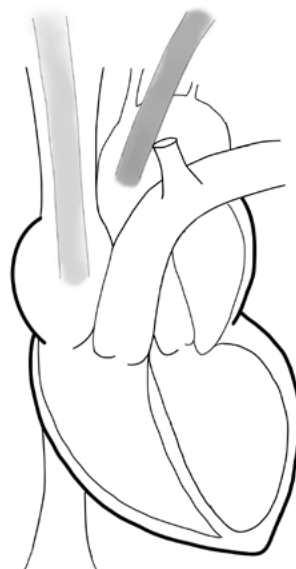


Figure 2. Central cannulation with venous access in the right atrium (drainage cannula - blue) and arterial access in the aorta (return cannula - red)

and levosimendan. Fluid resuscitation included colloid, blood, and blood products transfusions. Mean Arterial Pressure (MAP) was maintained above 40 mmHg, electrocardiography revealed a supraventricular, non-sinus rhythm. Mechanical ventilation with PEEP+10 was used. Echocardiography indicated severely impaired left ventricular (LV) function with no aortic valve opening. A decision was made to implant a left ventricular vent. In the operating room, the chest was reopened via the left atrium, and a venting cannula was implanted into the left ventricle. Post-procedure, the patient remained on mechanical ventilation, ECMO therapy, and circulatory support with reduced doses of inotropes. Anticoagulation was maintained with unfractionated heparin infusion. On the third day, parenteral nutrition and trophic enteral feeding were introduced. Since admission, diuresis was supported by continuous furosemide infusion as part of the planned regimen. Slightly elevated urea levels were observed, while creatinine remained within the normal range. As positive result for HHV-6 PCR was obtained, intravenous ganciclovir and intravenous immunoglobulins were administered. As a preventive measure during ECMO, vancomycin (with concentration monitoring) and ceftriaxone were administered according to the plan.

Echocardiographic assessments were repeated showing no visible improvement in left ventricular function.

Daily transfontanelle ultrasound examinations were performed, consistently yielding normal results. On the fourth day of ECMO therapy, transient discreet anisocoria was noted, and an urgent transcranial ultrasound revealed no pathology. The next day, features of bleeding diathesis with active bleeding from puncture sites and significant mediastinal drainage were observed. Blood and blood products were transfused, Exacyl was administered, and heparin infusion was reduced. A planned chest revision was carried out, ECMO flow was reduced, visually improving cardiac perfusion and contractile function. The decision was made to attempt ECMO weaning the following day. Ventilation was modified, infusions of adrenaline, noradrenaline, and dopamine were initiated.

The following day, in the morning hours, ECMO weaning was successfully performed without complications. Post-decannulation echocardiographic examination revealed generalized myocardial hypokinesis, no fluid in the pericardial sac or pleural cavities, left ventricular dilation (LVEDd) of 30 mm. The bicuspid

valve showed trace/mild regurgitation with a systolic gradient of 15 mmHg. Pulsatile flow in the descending aorta, Vmax 50 cm/second. Inferior vena cava (IVC) measured 8 mm. Reduced respiratory compliance. TAPSE was 5.4 mm, with decreased tissue Doppler imaging (TDI). Systemic RV velocity was 4.5 cm/s, and TDI E medial was 6.15 cm/second. Mitral valve inflow fusion wave - Vmax 82 cm/s. Heart rate was 166/min. Left ventricular end-diastolic volume (LVED Vol) was 22.8 ml, left ventricular end-systolic volume (LVEST Vol) was 20 ml, and left ventricular ejection fraction (LVEF) ranged from 9.6% to 13.2% (biplane).

On the next days, sedation was gradually reduced, leading to the patient opening her eyes and moving extremities. No concerning neurological symptoms were observed. Upon successful extubation, the patient was subsequently transferred to the Cardiology Department.

3 weeks after, the cardiac magnetic resonance imaging (cMRI) diagnosed dilated cardiomyopathy (DCM) without morphological signs of myocardial inflammation.

The patient undergone qualification for heart transplantation (HTx), then urgent application was submitted. About few days later information about a potential heart donor was received. Blood group compatibility between the donor and recipient was confirmed, parental consent for heart transplantation was obtained. Preparations for the procedure commenced. Considering the ECMO history, a four-drug immunosuppression regimen was administered.

The child successfully underwent a heart transplantation procedure about a month from cardiac arrest episode, and the process was free from complications.

Discussion

If the return of spontaneous circulation (ROSC) after cardiac arrest is not achievable despite effective conventional cardiopulmonary resuscitation, the chances of recovery are very low. One strategy used to increase survival is to perform venoarterial extracorporeal membrane oxygenation in these patients. VA-ECMO is a system that drains blood from the right atrium directly or through a cannula in the femoral vein and returns it to the patient's arterial system, usually via the femoral artery or directly into the aorta, after proper oxygenation. Extracorporeal cardiopulmonary

resuscitation is the use of VA-ECMO on patients who cannot be saved with traditional cardiopulmonary resuscitation. The goal of ECPR is to provide adequate perfusion to the end organs once potentially “reversible” problems have been addressed [4].

ECPR may be a life-saving procedure, but it carries significant risks. Therefore, it is important to determine which pediatric patients will benefit from ECPR. There are weak recommendations and very low certainty evidence in children.

According to The American Heart Association (AHA), ECPR in pediatric patients has been recommended for children with heart disease when the etiology of the cardiac arrest is considered to be “amenable to recovery or transplantation” [5].

It is suggested that ECPR can be used as a rescue therapy for selected patients with IHCA when conventional CPR fails to restore spontaneous circulation in settings where this can be implemented [6].

Resuscitation Council UK in their Paediatric advanced life support Guidelines states that ECPR should be considered early for children and infants with in-hospital cardiac arrest and a (presumed) reversible cause when conventional ALS does not immediately lead to ROSC in a healthcare situation where expertise, resources, and sustainable systems are available to initiate extracorporeal life support (ECLS) as soon as possible [7].

However, the literature regarding ECPR have consistently reported that both pediatric and adult patients with underlying cardiac illnesses are more likely to survive ECPR than those with non-cardiac illnesses [8].

This case presents a positive outcome of a patient who undoubtedly benefited from the ECMO therapy. Firstly, the patient was correctly classified, i.e. after a relatively short period of unsuccessful resuscitation, it was decided to implement ECMO support. According to Pediatric Extracorporeal Cardiopulmonary Resuscitation ELSO Guidelines from 2021 the time varies, but it is suggested to consider ECMO after 30-60 minutes of unsuccessful conventional resuscitation in refractory cardiac arrest in children [9].

Secondly, based on the presented symptoms, a cardiac cause of cardiac arrest was correctly suspected, which would have very likely led to the patient’s

death if special measures had not been undertaken. The patient suffered dilated cardiomyopathy which is characterized by left or both ventricular dilatation and contractile dysfunction with normal wall thickness. DCM is a significant risk factor for developing heart failure (HF) and is frequently associated with an increased risk of severe arrhythmias, indicating pathological involvement of the cardiac conduction system [10]. The purpose of ECPR is to provide replacement of the circulatory activity of the myocardium and the respiratory activity of the lungs resulting in survival with good neurological outcome.

Finally, the patient was free of complications thanks to professional care of qualified team and reasonable qualification for the procedure. We still face many complications during ECMO that occur bleeding (from the cannulation site, intracranial bleed, gut bleed, nasal bleed or alveolar haemorrhage), vascular injury during cannulation, aberrant placement of the cannula and unsuccessful cannulation, leg ischaemia, intracerebral haemorrhage (ICH)/stroke, renal failure or sepsis [11]. That implies how crucial is to select suitable candidates for ECPR.

It is also important to consider ethical issues before implementation of ECPR and while withdrawing the support when the ECPR is unavailing. The success of ECMO therapy requires a team effort of multidisciplinary specialists, highly trained healthcare professionals and adequate infrastructure with appropriate equipment.

Summary

This case report demonstrates a positive outcome in a young, critically ill patient after judicious application of ECMO for cardiac arrest due to acute heart failure.

According to The International Liaison Committee on Resuscitation (ILCOR) 2023 recommendations it is suggested to consider ECPR as a last-resort option for selected patients with in-hospital cardiac arrest, when conventional CPR is ineffective in restoring spontaneous circulation in conditions in which this can be implemented [6]. Our case support ILCOR recommendations to consider ECPR in children with cardiac disease in a center with the required equipment and qualified team.

Conflict of interest

None

ORCID

Aleksandra Kalicka 0009-0005-8287-8064

Michał Buczyński 0000-0001-8796-546X

Maciej Kaszyński 0000-0002-6020-5740

Izabela Pągowska-Klimek 0000-0002-4323-7214

Correspondence address

✉ Aleksandra Kalicka

Department of Pediatric Anesthesiology and Intensive Care, Medical University of Warsaw

ul. Żwirki i Wigury 63A, 02-091 Warszawa

☎ (+48 22) 317 98 61

✉ dz_anestezja.dsk@uckwum.pl

References

1. Voorde PV de, Turner NM, Djakow J, et al. European Resuscitation Council Guidelines 2021: Paediatric Life Support. *Resuscitation* 2021;161:327-87.
2. López-Herce J, del Castillo J, Matamoros M, et al. Factors associated with mortality in pediatric in-hospital cardiac arrest: a prospective multicenter multinational observational study. *Intensive Care Medicine* 2012;39:309-18.
3. Kumar KM. ECPR—extracorporeal cardiopulmonary resuscitation. *Indian J Thorac Cardiovasc Surg* 2021; 37: 294-302.
4. Barsan WG, Levy RC. Experimental design for study of cardiopulmonary resuscitation in dogs. *Ann Emerg Med* 1981;10:135-7.
5. Duff JP, Topjian AA, Berg MD, et al. 2019 American Heart Association Focused Update on Pediatric Advanced Life Support: An Update to the American Heart Association Guidelines for Cardiopulmonary Resuscitation and Emergency Cardiovascular Care. *Circulation* 2019;140:904-14.
6. Berg KM, Bray JE, Ng KC, et al. 2023 International Consensus on Cardiopulmonary Resuscitation and Emergency Cardiovascular Care Science With Treatment Recommendations: Summary From the Basic Life Support; Advanced Life Support; Pediatric Life Support; Neonatal Life Support; Education, Implementation, and Teams; and First Aid Task Forces. *Circulation* 2023;148:187-280.
7. Skellett S, Maconochie I, Bingham B, et al. Resuscitation Council UK. 2021 Resuscitation Guidelines. Paediatric Advanced Life Support Guidelines. <https://www.resus.org.uk/library/2021-resuscitation-guidelines>.
8. Alsoufi B, Al-Radi OO, Nazer RI, et al. Survival outcomes after rescue extracorporeal cardiopulmonary resuscitation in pediatric patients with refractory cardiac arrest. *J Thorac Cardiovasc Surg* 2007;134:952-9.
9. Guerguerian AM, Sano M, Todd M, et al. Pediatric Extracorporeal Cardiopulmonary Resuscitation ELSO Guidelines. *ASAIO Journal*. 2021;67:229-37.
10. McNally EM, Mestroni L. Dilated Cardiomyopathy. *Circ Res* 2017;121:731-48.
11. Li Z, Gao J, Wang J, Xie H, et al. Mortality risk factors in patients receiving ECPR after cardiac arrest: Development and validation of a clinical prognostic prediction model. *Am J Emerg Med* 2024;76:111-22.